

EP CASE REPORT

Zero-fluoroscopy trans-septal puncture and catheter ablation of a left atrial tachycardia in a pregnant woman with a prosthetic mitral valve

Pierre Ollitrault^{1*}, Arnaud Pellissier¹, Virginie Ferchaud^{1,2}, Justine Havard³, Laure Champ-Rigot¹, and Paul Milliez^{1,2}

¹Department of Cardiology, Caen Regional University Hospital, Avenue de la Côte de Nacre, 14000 Caen, Normandy, France; ²University of Caen Normandy, F-14000 Caen, France; and ³Biosense Webster, F-92787 Issy-les-Moulineaux, France

* Corresponding author. Tel: + 33 (0)2 31 06 51 18; fax: +33 (0)2 31 06 44 18. E-mail address: ollitrault-p@chu-caen.fr

We present the case of a 39-year-old woman with previous biological mitral valve replacement (at age 32; for rheumatic heart disease) and left atrial tachycardia radiofrequency catheter ablation (at age 37; pulmonary vein isolation and roof line). During her 16th week of pregnancy, she was referred for catheter ablation of a persistent symptomatic drug-refractory atrial tachycardia. The procedure was performed under general anaesthesia with endotracheal intubation and uninterrupted low molecular-weight heparin. Preprocedural transoesophageal echocardiography (TOE) was performed to rule-out intra-atrial thrombus. Right atrial geometry and computer matrix creation were performed using PentarayTM multi-electrode catheter and Carto3 V7TM electroanatomic mapping system (Biosense Webster, Diamond Bar, CA, USA). A decapolar steerable catheter was positioned in the right atrial appendage. Trans-septal puncture was performed using a visualizable steerable sheath (VizigoTM, Biosense Webster, Diamond Bar, CA, USA) under TOE guidance (Figure 1A, Supplementary material online, Video S1). Activation map of the left atrium found a 280 ms-cycle-length left anterior macro-reentry (Figure 1B, Supplementary material online, Video S2). Voltage map showed a large anterior scar zone, isolated pulmonary veins, and block along the roof line. The first radiofrequency application on the anterior wall of the left atrium with a 4 mm irrigated-tip catheter (40 W, ThermoCool SmartTouchTM, Biosense Webster, Diamond Bar, CA, USA) terminated tachycardia (Supplementary material online, Video S3). An anterior line was performed from the mitral annulus at 12 o'clock to the left superior pulmonary vein. Intra-atrial re-entrant tachycardia was not inducible at baseline and after isoproterenol infusion, with a complete block along the anterior line. Procedure lasted 150 min (ablation time 12 min, fluoroscopy 0 s), with favourable outcome for both the foetus and the mother.

Supraventricular tachycardias are rare during pregnancy, with an estimated incidence of 23/100 000 pregnancies. Anti-arrhythmic drugs might have adverse effects on the foetus, and catheter ablation should be considered in case of drug-refractory or poorly tolerated tachycardia in experienced centres^{1,2}. The lowest fluoroscopy use is advisable ("fluorless") in order to limit foetal X-ray exposure, but this attitude might be limited during critical steps such as a trans-septal puncture or when navigating near critical structures such as a prosthetic mitral valve³. In this case, we highlighted the safety of zero-fluoroscopy trans-septal puncture and catheter ablation in the left atrium, using fully visualizable catheters and steerable sheath, in a pregnant woman.

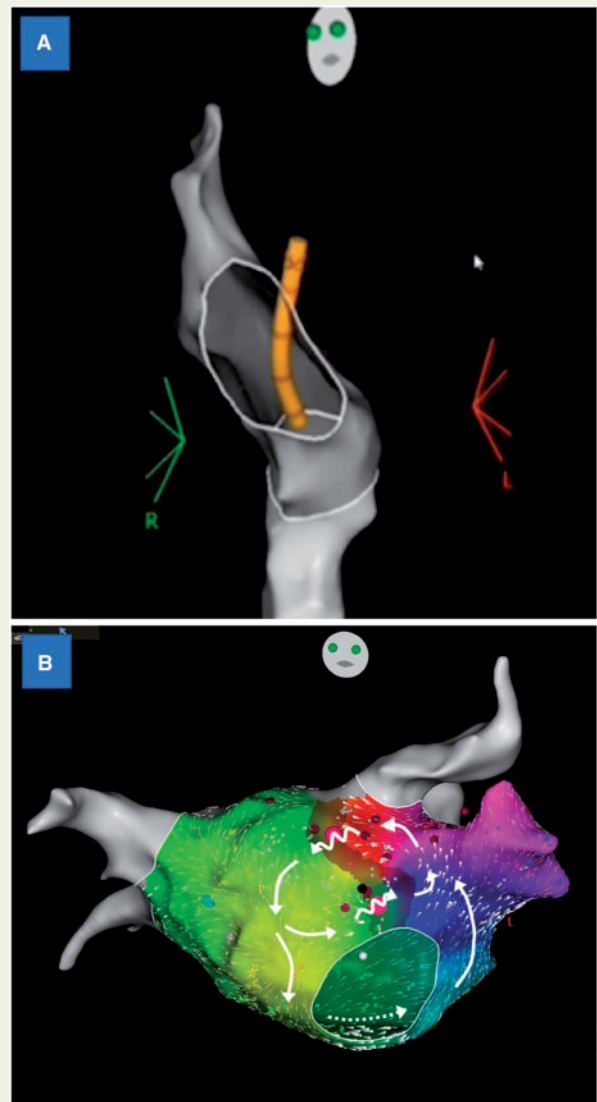


Figure 1 (A) Zero-fluoroscopy trans-septal puncture with the visualizable sheath in left anterior oblique view; (B) activation map of the left atrium in anteroposterior view.

Supplementary material

Supplementary material is available at *Europace* online.

Conflict of interest: J.H. is an employee of Biosense Webster.

References

1. Brugada J, Katritsis DG, Arbelo E, Arribas F, Bax JJ, Blomström-Lundqvist C et al. 2019 ESC Guidelines for the management of patients with supraventricular tachycardia. *Eur Heart J* 2019;**00**:1–65.
2. Li MM, Sang CH, Jiang CX, Guo XY, Li SN, Wang W et al. Maternal arrhythmia in structurally normal heart: prevalence and feasibility of catheter ablation without fluoroscopy. *Pacing Clin Electrophysiol* 2019;**42**:1566–7.
3. Pani A, Belotti G, Bonanno C, Bongiorno MG, Bottoni N, Brambilla R et al. Predictors of zero X-ray ablation for supraventricular tachycardias in a nationwide multicenter experience. *Circ Arrhythm Electrophysiol* 2018;**11**:e005592.